Biology of Hair and Nails 68



Etienne C.E. Wang, David de Berker and Angela M. Christiano

Key features

- The pilosebaceous unit and nail apparatus are epidermal derivatives that produce two of the hardest epithelial structures in mammalian biology
- The hair follicle is the only continuously cycling organ in mammals, while the nail exhibits uninterrupted growth
- Hair and nails serve multiple functions, including protection, sensation, and social communication
- Hair shafts and nail plates largely consist of dead, terminally differentiated keratinocytes (trichocytes and onychocytes, respectively) whose durability is based on the presence of abundant keratin intermediate filaments
- The hair cycle includes phases of growth (anagen), regression (catagen), resting (telogen), and hair shaft shedding (exogen/teloptosis)
- The hair follicle is a site of immune privilege and a major reservoir for epithelial and melanocyte stem cells; immune privilege and stem cells within the nail unit are also becoming recognized
- The nail apparatus consists of the fully cornified nail plate, which is produced by the nail matrix, and other specialized epithelial tissues such as the nail bed and nail folds

PRINCIPLES OF ADNEXAL MORPHOGENESIS

Skin adnexa in mammals develop through evolutionarily conserved mechanisms. Similar processes lead to modifications of epithelial cells and proteins in order to form functional structures such as hairs, feathers, nails, glands, and teeth. In all cases, adnexa result from interactions between adjacent tissue layers, the ectoderm (epidermis) and underlying mesoderm (dermis) (Fig. 68.1). For example, the hair follicle (HF) first arises as a small epidermal bud and then, via reciprocal signaling involving the underlying dermis, progresses to form a complex, multi-cylindrical organ with associated sebaceous and apocrine glands (see Fig. 2.4). The developmental relationships among different adnexal structures is evidenced by the hair, nail, sweat gland, and tooth defects observed in ectodermal dysplasias (see Ch. 63).

The basic principles of adnexal development were defined by a series of classic tissue recombination experiments performed in the 1970s, which have served as the foundation for research in this field[1,2]. These experiments demonstrated that the dermal mesenchyme emits the initial "message" for the development of all types of skin adnexa (stage 0). The mesenchyme itself does not change morphologically but rather signals the overlying epithelium to thicken and form a placode (stage 1) (Fig. 68.2). The type of appendage that develops is determined within the epidermis, where positional and epigenetic cues dictate the ultimate phenotype[3]. Canonical β-catenin-dependent WNT (*w*ingless-type i*nt*egration site) signals are candidates for the dermal message, and it is thought that they precede other activators and regulators of adnexal development[4]. Recent advances in single-cell RNA sequencing and the study of increasingly smaller cellular subsets have confirmed the developmental trajectory of an early dermal condensate that drives appendageal morphogenesis[5,6].

BIOLOGY OF HAIR

Hair Follicle Morphogenesis

WNT signaling plays key roles in HF development. In mice, lack of WNT signaling through overexpression of the WNT inhibitor Dickkopf homolog 1 (DKK1) prevents HF formation[4], while overexpression of β-catenin in the epidermis (acting downstream of WNT; see Fig. 55.6) promotes conversion to a placode fate[7]. Loss-of-function mutations in *WNT10A*, which encodes an activator of WNT signaling, cause several forms of ectodermal dysplasia in humans, including odonto-onychodermal dysplasia and Schöpf–Schulz–Passarge syndrome (see Ch. 63). The spectrum of cutaneous findings that can result from *WNT10A* mutations includes hypotrichosis, nail dystrophy, palmoplantar keratoderma with eccrine syringofibroadenomatosis, and apocrine hidrocystomas[8]; in addition, *WNT10A* polymorphisms have been associated with hair shape, tooth morphology, and corneal thickness[9,10]. The APCDD1 (adenomatosis polyposis coli downregulated 1) protein normally inhibits WNT/β-catenin signaling by binding to WNT and low-density lipoprotein receptor-related proteins (LRPs) upstream of β-catenin. *APCDD1* mutations that lead to dysregulation of the WNT/β-catenin pathway result in hypotrichosis simplex characterized by hair shaft miniaturization (see Fig. 55.6)[11].

In normal mouse HF development, WNT and β-catenin activation occurs in the placode following the initial dermal signal. This induces transcription of the ectodysplasin A receptor gene (*Edar*), which mediates nuclear factor-κB (NF-κB) signaling[12]. Expression of EDAR within the primary follicle placode also suppresses inhibitory signals from the surrounding epidermis, which refines WNT/β-catenin expression within the placode. Competing gradients of WNT (activating) and DKK (inhibitory) signals within the epidermis modulate HF spacing, establishing regular intervals between follicles[13,14].

After determination of placode fate, reciprocal signaling between the mesenchyme and epithelium continue to drive HF morphogenesis through a complex interplay among secreted molecules (see Fig. 68.2). Fibroblast growth factor (FGF)-20 secreted by the placode promotes formation of a dermal condensate[15]. A second dermal signal follows,

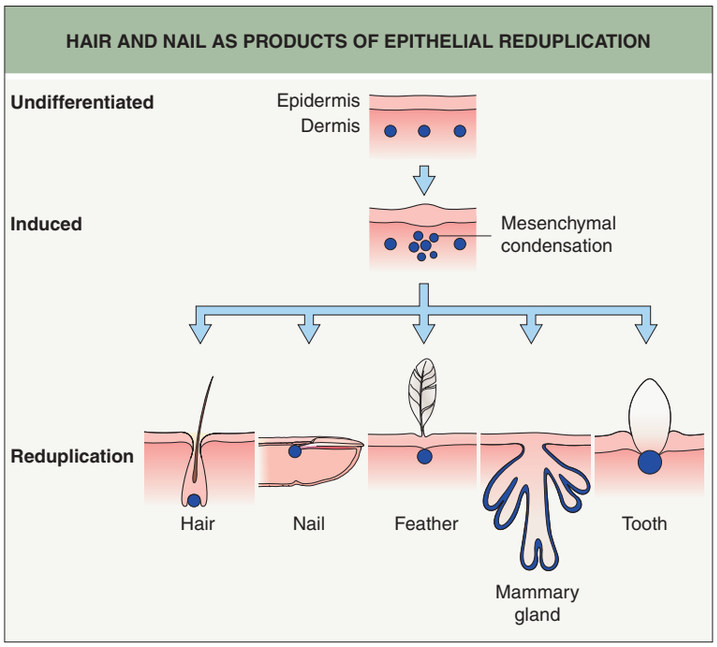

Fig. 68.1 Hair and nail as products of epithelial reduplication. *Reproduced with permission from Chuong C-M. Morphogenesis of epithelial appendages: variations on top of a common theme and implications in regeneration. In: Chuong C-M (ed). Molecular Basis of Epithelial Appendage Morphogenesis. Austin: R.G. Landes Company, 1998:3–13.*

Downloaded for Anonymous User (n/a) at Egyptian Knowledge Bank from ClinicalKey.com by Elsevier on March 10, 2024. For personal use only. No other uses without permission. Copyright ©2024. Elsevier Inc. All rights reserved.

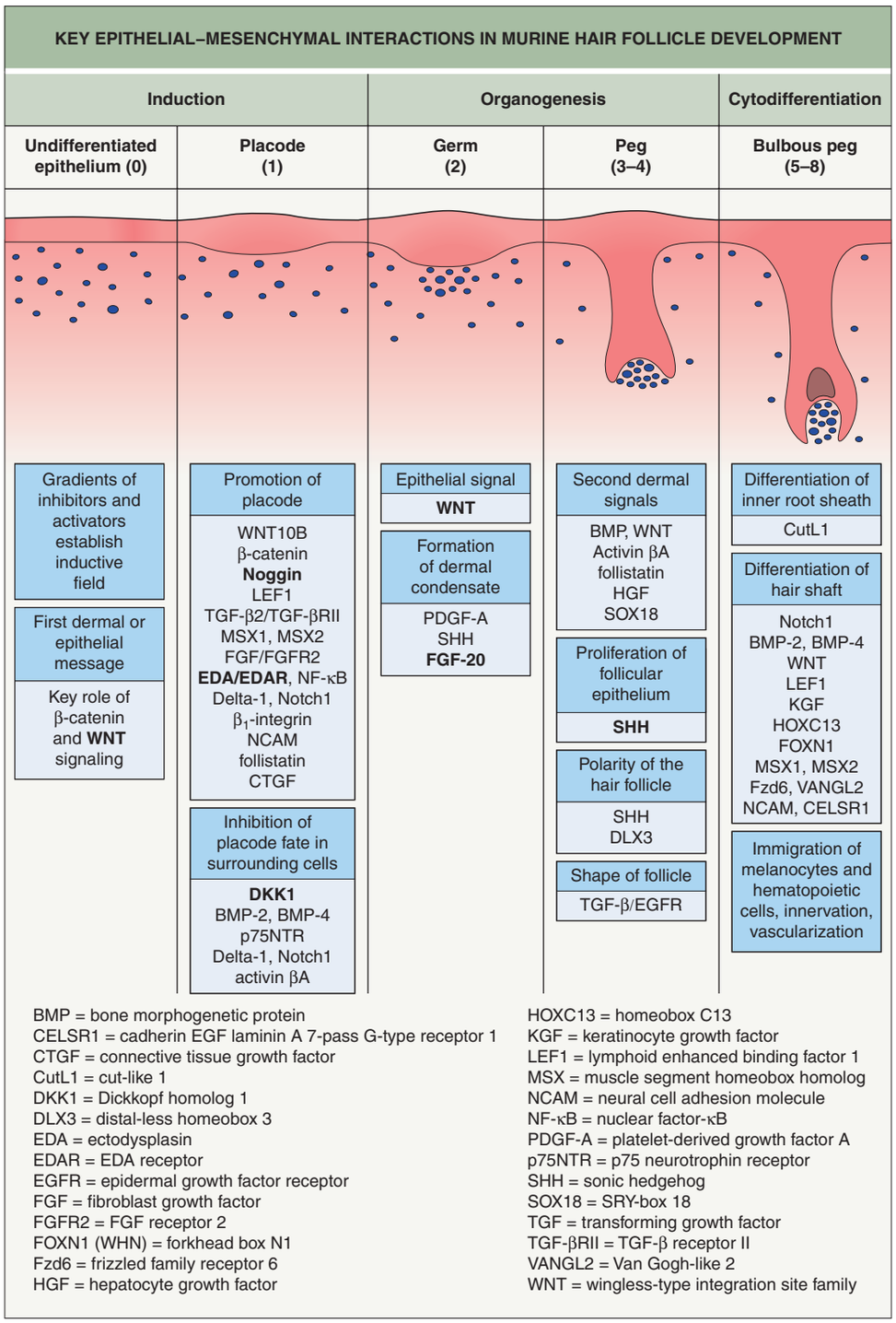

Fig. 68.2 Key epithelial–mesenchymal interactions in murine hair follicle development. The undifferentiated epithelium emits an as-yet unidentified initial signal affecting the WNT pathway, which leads to accumulation of β-catenin in the superficial dermis. Dermal cells respond with secretion of morphogens such as WNTs, ectodysplasin A (EDA), and fibroblast growth factors (FGFs) that lead to specification of the epidermal placode. The placode produces Dickkopf homolog (DKK) and bone morphogenic proteins (BMPs) that inhibit surrounding epithelial cells, thus refining the patterning. The placode matures into the primary hair germ, and its secretion of platelet-derived growth factor A (PDGF-A), sonic hedgehog (SHH), and FGF-20 promote condensation of the dermal cells. Signals from the dermal condensate include WNTs, SHH, and hepatocyte growth factor (HGF); this initiates downgrowth of the hair germ to form the peg, which envelopes the condensate and tightens the interaction interface. Subsequent cross-talk activates a host of morphogens that direct differentiation of the bulbous peg into concentric layers of keratinocytes that ultimately form the hair follicle. *Adapted from Millar SE. Molecular mechanisms regulating hair follicle development. J Invest Dermatol 2002;118:216–25.*

which induces proliferation of the epidermis and invasion of the dermis by a column of epithelial cells that forms the hair germ (stage 2), followed by the hair peg (stage 3–4) and subsequently the bulbous peg (stage 5–8) (see Fig. 68.2)[16]. WNT and EDAR signaling control the expression of sonic hedgehog (SHH), which drives downgrowth of the hair germ[17]. Primary cilia on dermal cells within the condensate coordinate SHH signaling. In mice that lack SHH or have abnormal cilia, the dermal condensate forms but proliferation and downgrowth of the epithelium are arrested[18,19]. Hemidesmosomal integrins also have a physical role in hair germ development, and mice with deficient β1 or β4 integrins have hair germs that cannot remodel their basement membrane and descend into the dermis[20,21].

During follicle development, the mesenchymal condensate is progressively engulfed by epidermal cells and becomes enclosed, thereby evolving into the dermal papilla. Although epithelial growth is initially downward, a switch to an upward differentiation program occurs in response to WNT and bone morphogenic protein (BMP) signaling from the dermal papilla. This gives rise to concentric layers of the hair shaft and inner root sheath. In human hair follicles, epithelial keratins 1, 10, 14, and 16 are expressed by 12 weeks' gestational age, with keratin 16 in proliferative regions such as the bulb; this is followed by keratin 20 expression. Epithelial cell fate depends upon the relative position of a matrix cell with respect to the dermal papilla[22]. An early effector of this signaling within the matrix is the distal-less homeobox 3 (DLX3) transcription factor, which directly regulates expression of hair keratin genes in the hair shaft and inner root sheath[23]. A dominant frame-shift mutation in *DLX3* results in tricho-dento-osseous syndrome, a form of ectodermal dysplasia characterized by dystrophic hair, enamel hypoplasia, and thickening of skull and jaw bones[24]. Mutations in additional genes with key roles in hair follicle development underlie other ectodermal dysplasias as well as non-syndromic hair disorders (see Ch. 63 and Table 69.7).

Downloaded for Anonymous User (n/a) at Egyptian Knowledge Bank from ClinicalKey.com by Elsevier on March 10, 2024. For personal use only. No other uses without permission. Copyright ©2024. Elsevier Inc. All rights reserved.

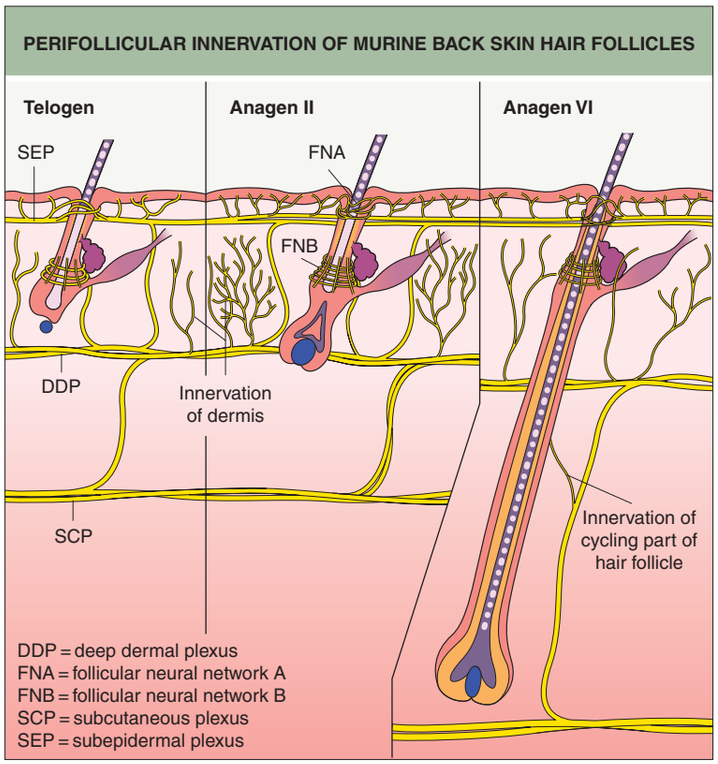

Fig. 68.3 Perifollicular innervation of murine back skin hair follicles. *Adapted from Paus R, Peters EM, Eichmüller S, Botchkarev VA. Neural mechanisms of hair growth control. J Invest Dermatol Symp Proc. 1997;2:61–8.*

Complex neural networks develop in conjunction with HF morphogenesis. Nerve fibers arrive in the skin first and are located at presumptive follicular sites, running parallel to a dense network of blood vessels (Fig. 68.3). Developing follicles become innervated around stage 5, with nerve fibers encircling the isthmus and bulge regions[25]. Neurotrophins released from the follicular epithelium regulate this innervation, and in turn the nerves may influence the stem cell niche of the HF[26]. Similarly, signaling proteins that promote angiogenesis, such as vascular endothelial growth factor (VEGF), are released from the epithelium and affect development of the vascular network surrounding HFs[27].

Hair follicle patterning

Individual mammals can produce different types of hairs that share basic architectural principles. In the dorsal skin of mice, HF development occurs in three successive waves: (1) large, straight, *primary guard* or *tylotrich* hairs, which comprise 1%–3% of total hairs and have two sebaceous glands, form on embryonic day 14.5; (2) *secondary awl* (straight, ~30% of the coat) and *auchene* (one bend, ~0.1% of the coat) hairs form on embryonic day 16.5; and (3) *tertiary zigzag* hairs, which have several bends and account for ~70% of the coat, form on embryonic day 18.5. The mouse coat therefore contains four distinct hair types, in addition to specialized hairs such as vibrissae (whiskers) and tail hairs[28]. EDAR is necessary for placode development in primary HFs[29] but not for induction of secondary HFs, which utilize signaling pathways that involve Noggin and SRY-box 18 (SOX18) expression within the dermal papillae[29–31].

In humans, hypohidrotic ectodermal dysplasia (HED) with abnormal morphogenesis of scalp hair, sweat glands, and teeth results from mutations in the genes encoding components of the EDAR/NF-κB signaling pathway, including EDAR, its ligand ectodysplasin A, and the downstream effector EDAR-associated death domain (EDARADD)[32] (see Fig. 63.15). In addition, a non-synonymous single nucleotide polymorphism (SNP) within *EDAR* is associated with increased hair thickness in Asian populations[33]. Deep deformations in the hair shaft were identified in Swedish patients with an autosomal dominant form of HED due to an *EDAR* mutation[34]. These clinical observations underscore the importance of the EDAR/NF-κB signaling pathway in human appendage development. Interestingly, mutations in human *SOX18* cause lymphedema and telangiectasias as well as hypotrichosis[35].

The hairs of the mouse dorsal coat have anterior–posterior polarity along the body axis, which contributes to formation of a sleek coat. SHH and neural cell adhesion molecule (NCAM) within the HF have an asymmetric distribution pattern, which is established by a conserved planar cell polarity (PCP) pathway during hair germ development[36]. PCP proteins VANGL2 (Van Gogh-like 2) and CELSR1 (cadherin epidermal growth factor laminin A seven-pass G-type receptor 1) respond to directional cues and are necessary for the correct polarization of follicles within the skin[36,37]. Mutations in *Vangl2* or the frizzled family receptor 6 (*Fzd6*) affect the early global alignment of HFs, resulting in germs that first grow vertically. Over time the follicles reorient themselves in competing patterns, producing characteristic whorls on the back of the mouse[38]. In *Fzd6*$^{-/-}$ mice, an additional mutation in Astrotactin2 (*Astn2*), which has roles in neuronal migration, leads to a 180-degree reorientation of the dorsal coat to a posterior–anterior polarity[39]. Hair whorls are frequently observed in mammals, such as on the occipital scalp in humans, between the eyes in horses and cattle, and on the upper chest in dogs[38]. Aberrant or displaced hair whorls are observed in a number of genetic disorders (omim.org).

Under physiologic conditions, human HF morphogenesis occurs only once. Lanugo, vellus, and terminal hairs have the same basic architecture (Table 68.1). The first "coat" is composed of fine, long, variably pigmented lanugo hair, which is shed in an anterior-to-posterior wave during the third trimester. A second coat of fine, shorter, unpigmented lanugo hair then grows in all areas except the scalp and is shed 3–4 months after birth; pigmented scalp hairs, which have variable lengths and diameters, are also shed postnatally in an anterior-to-posterior wave. Thereafter, the hair grows in an asynchronous "mosaic" pattern rather than waves. In prepubertal children, hair is terminal on the scalp, eyelashes, and eyebrows, while it is vellus on the face, trunk, and extremities. During puberty, vellus hairs in some sites become terminal hairs under the influence of androgens. Paradoxically, terminal hairs on the scalp exposed to the same androgens revert to miniaturized vellus-like hairs in androgenetic alopecia.

Congenital generalized hypertrichosis (Ambras syndrome) is characterized by a disruption in the patterning of hairs, with terminal hairs growing at sites that normally have vellus follicles[40]. A position effect that downregulates the expression of the trichorhinophalangeal syndrome I gene (*TRPS1*) was found to underlie this hypertrichosis phenotype in both humans and mice[41]. In addition, X-linked congenital generalized hypertrichosis in a Mexican family was associated with a position effect that decreased the expression of *FGF13*[42].

In most mammals, the hair pattern differs depending on the body site. While the ectoderm involved in skin and hair development is non-neural and relatively homogeneous, the mesenchyme has various origins which may explain this regionalization. The dorsal dermis is derived from the somitic dermomyotome, the ventral dermis has a somatopleural origin, and the craniofacial dermis arises from the neural crest[43,44]. The dermal progenitors at each of these sites are specified by different signaling pathways. Mice display regional differences in skin thickness as well as hair color and type. The postnatal identity of their skin is acquired by embryonic day 12.5, with the T-box 15 (TBX15) transcription factor appearing within dorsal skin to demarcate the dorsal–ventral boundary[45].

In humans, the effects of androgens on HFs depend upon the body site. Follicles in the frontal scalp are normally androgen-dependent, whereas occipital scalp follicles are hormonally insensitive and therefore less susceptible to androgenetic alopecia. When HFs from the occipital scalp are transplanted to the frontal scalp, they typically retain the pigmentary characteristics, androgen sensitivity, and growth rate of the donor site[46]. However, in other instances, transplanted hairs take on characteristics of the recipient site, such as scalp hairs moved into the eyebrow region. It remains to be established exactly which characteristics are more influenced by the recipient site versus the donor site following transplantation.

Postnatal hair follicle development

Although HF formation in general occurs prior to birth, adult mammalian skin retains the capacity for HF morphogenesis. In adult mouse and rabbit skin, WNT-dependent *de novo* HF formation occurs after wounding[47]; this is mediated by FGF-9 secreted by infiltrating γδ-T cells and wound

Downloaded for Anonymous User (n/a) at Egyptian Knowledge Bank from ClinicalKey.com by Elsevier on March 10, 2024. For personal use only. No other uses without permission. Copyright ©2024. Elsevier Inc. All rights reserved.

TRICHOLOGY TERMS	
Hair follicle (HF) cycle	Autonomous, rhythmic transformation of fully developed HFs through phases of growth, regression, and resting; controlled by the follicle itself by an as yet enigmatic "hair cycle clock", with modulation by numerous systemic/extrafollicular factors
Anagen	Growth stage of the HF cycle
Catagen	Involution of the lower two-thirds of the HF by massive keratinocyte apoptosis
Telogen	Resting phase of the HF cycle
Exogen	Phase of active hair shaft shedding (during anagen in rodents; most likely during the telogen to anagen transition in humans)
Kenogen	Telogen follicle with no club hair present
Hair bulb	Lowermost portion of the HF
Hair matrix	Rapidly proliferating keratinocytes that terminally differentiate to produce the hair shaft
Club hair/fiber	Fully keratinized proximal tip of hair shaft, formed during late catagen and telogen; brush-like appearance; characteristic of telogen follicles
Vellus hair (follicle)	Very short, non-pigmented, and usually non-medullated; absence of arrector pili muscle; tiny vellus follicles can have large sebaceous glands (face); undergo full hair cycle, yet much shorter than terminal hair
Terminal hair	Large, usually pigmented and medullated hair
Lanugo hair	Fine hair on the fetal body; shed *in utero* or during the first weeks of life
Vibrissae	Special sensory HFs found on the upper lips/snout region in non-human mammals, especially rodents; largest and most densely innervated HFs with special sinusoid blood supply; first HFs to develop
Tylotrich HF	Large sensory HFs interspersed within truncal skin of non-human mammals, most notably rodents; extra large, long hair shaft, typically associated with double sebaceous gland and an innervated epidermal Merkel cell complex (Pinkus' Haarscheibe); second type of HF to develop
Non-tylotrich pelage hair	Majority of all HFs in non-human mammals; last to develop
Effluvium	Process of excessive shedding of hair shafts
Alopecia	Result of abnormal hair loss
Hirsutism	Excessive vellus-to-terminal hair conversion in androgen-dependent areas in women
Miniaturization	Terminal-to-vellus hair conversion, e.g. on the balding scalp in androgenetic alopecia; these miniaturized follicles still have an arrector pili muscle, unlike true vellus hairs
Infundibulum of follicle	Region extending from the junction with the interfollicular epidermis to the opening of the sebaceous gland; displays cornification similar to that of the interfollicular epidermis
Isthmus of follicle	Region located between the opening of the sebaceous gland and the site of insertion of the arrector pili muscle; displays trichilemmal keratinization
Arrector pili muscle	Inserts at the level of the bulge; pulls up hair ("goose bumps")
Bulge	Segment of the outer root sheath located at the level of arrector pili muscle insertion; major seat of epithelial stem cells of the HF
Secondary hair germ	Additional seat of epithelial stem cells and site of melanocyte stem cells; located between club hair and dermal papilla in telogen HF
Dermal sheath	Special mesenchymal follicular sheath that is tightly attached to the HF basement membrane and is continuous with the follicular dermal papilla
Follicular dermal papilla (DP)	Onion-shaped, closely packed, specialized fibroblast population with inductive and morphogenic properties; hair cycle-dependent fibroblast trafficking occurs between the dermal sheath and DP; volume of DP determines size of hair bulb and, thus, hair shaft diameter
Inner root sheath (IRS)	Packages and guides the hair shaft; cornifies
Outer root sheath (ORS)	Merges distally into the epidermis and proximally into the hair bulb; provides slippage plane, nutrition, regulatory molecules, and stem cells
Follicle pigmentary unit	Melanin-producing HF melanocytes located above and around the upper one-third of the DP; transfer eu- or pheomelanosomes to differentiating HF keratinocytes in the precortical matrix; goes largely into apoptosis during each catagen phase, regenerated from melanocyte stem cells in hair germ (and possibly from non-melanogenic ORS melanocytes) during anagen

Table 68.1 Trichology terms. *Courtesy John P. Sundberg, DVM, PhD.*

fibroblasts[48]. WNT-dependent expression of FGFs may also play a role in human hair follicle regeneration[49]. It is therefore reasonable to consider possible therapeutic interventions that would initiate *de novo* HF formation on the human scalp[50]. Trans-species end-bulb formation and hair fiber growth has been demonstrated after implantation of intact human dermal papillae onto transected mouse whisker follicles[51]. In humans, allogeneic transplantation of tissue from the dermal sheath that surrounds the dermal papilla can induce new follicle formation in the recipient, with immune privilege providing protection from rejection[52]. In addition, cultured tooth mesenchymal papilla cells from humans and rats have been shown to induce hair fiber formation in an amputated follicle, highlighting the conservation of inductive signals among different adnexa[53].

Dermal papilla cells in rodents show much more inductive potency than their human counterparts. Rodent HF papilla cells can reprogram differentiated glabrous epidermis to produce a *de novo* HF, and they are also capable of initiating transdifferentiation of amnion or even adult corneal epithelium into epidermis complete with HFs[54,55]. Human dermal papilla cells lose their inductive properties quickly in a standard monolayer culture, which hampers the utilization of these cells for hair regeneration. However, dermal papilla cells grown in a three-dimensional spheroid culture have been shown to retain their ability to induce hair growth in glabrous skin, suggesting that cellular interactions are critical to maintenance of dermal papilla identity[56].

Downloaded for Anonymous User (n/a) at Egyptian Knowledge Bank from ClinicalKey.com by Elsevier on March 10, 2024. For personal use only. No other uses without permission. Copyright ©2024. Elsevier Inc. All rights reserved.

The Mature Hair Follicle: Cycling and Anatomy

Once the mature HF is generated during embryogenesis and early postnatal life, it begins to cycle and continues to do so throughout its lifetime. The phases of the hair cycle include active growth (anagen), regression (catagen), and rest (telogen) (Fig. 68.4A). As noted above, mouse follicles cycle in a synchronous wave along the anterior to posterior axis, while human follicles cycle in a mosaic pattern. HF cycling is an autonomous phenomenon that continues even when HF units are isolated from the skin and grown in culture[57]. Signaling pathways involved in HF morphogenesis, including those mediated by WNT and FGFs, also regulate the mature hair cycle[58]. The portion of

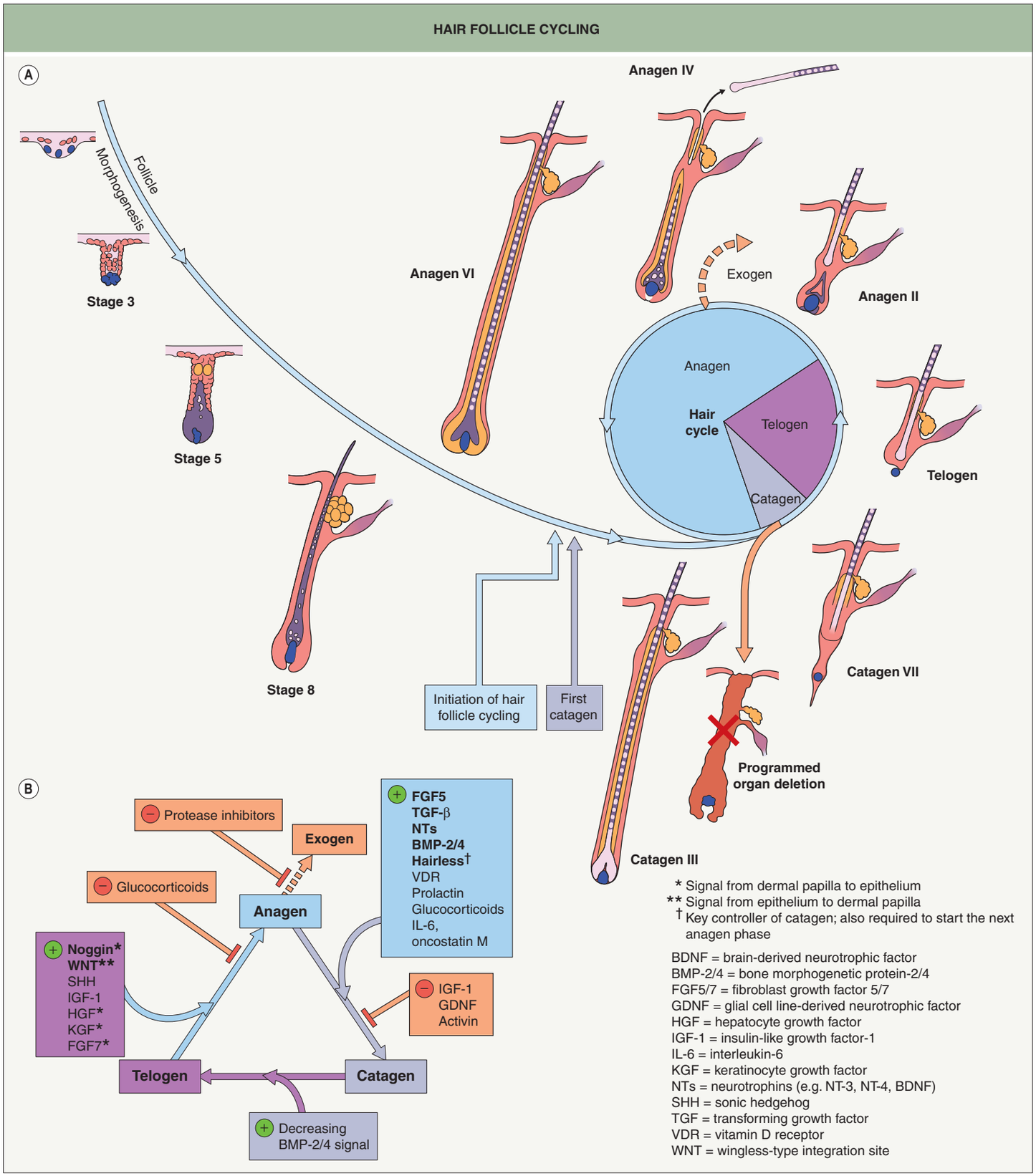

Fig. 68.4 Hair follicle cycling. A Model of hair follicle development and cycling. Although exogen is coupled to anagen in rodents, the timing of exogen in humans is less well characterized, and the club fiber is thought to usually be shed during the telogen to anagen transition. **B** Regulation of hair.

Downloaded for Anonymous User (n/a) at Egyptian Knowledge Bank from ClinicalKey.com by Elsevier on March 10, 2024. For personal use only. No other uses without permission. Copyright ©2024. Elsevier Inc. All rights reserved.

the follicle below the bulge undergoes distinct morphologic changes as it grows and regresses; in contrast, the upper region of the follicle including the sebaceous gland, isthmus, infundibulum, and hair canal remains permanent.

The process of cycling makes the HF a dynamic structure, enabling animals to have different hair lengths depending on the body site and to change their coats depending on the season for camouflage and insulation (Table 68.2). Coat changes involve two processes: (1) exogen – signals and structural changes culminating in hair shedding (teloptosis); and (2) initiation of new hair fiber growth[59]. "Kenogen" refers to a telogen follicle that has lost its club fiber but has not yet transitioned to anagen, representing the "true" resting phase of the hair cycle where metabolic activity is at a minimum.

Anagen

Anagen is the period of active hair fiber production, and its duration varies depending upon factors such as species and body site (Table 68.3). Anagen is divided into six substages, anagen I–VI; it lasts 1–3 weeks in mice and up to several years on the human scalp[60,61], explaining the longer lengths of human scalp hair. The start of anagen (anagen I), as observed in mouse skin, is associated with an increased size of the dermal papilla, due mainly to an influx of cells from the surrounding dermal sheath. Dermal sheath cells at the base of the follicle also contribute to dermal papilla regeneration after removal of the lower follicle[62,63]. The influx of cells at the start of anagen is accompanied by an increase in ECM material. This doubles the size of the dermal papilla[64], the width of which is directly proportional to the thickness of the hair shaft produced by the follicle. The degree of axial symmetry within the hair bulb determines the curvature of the final hair structure[65].

The dermal papilla provides signals to the surrounding matrix cells, whose position with respect to the dermal papilla specifies their fate, e.g. central cells become the medulla[22]. As the matrix cells begin to differentiate, they form precursor cells of the different follicle lineages. Migrating upwards, these cells undergo specialized programs of differentiation, expressing specific sets of keratins to form seven concentric epithelial lineages of the follicle, from the medulla to the companion layer (Figs. 68.5 and 68.6). In contrast, the outer root sheath (ORS), which is the outermost layer of the epidermal portion of the follicle, does not originate from upward growth of matrix cells, but rather directly from the bulge (see below)[66]. The growing HF ends up nestled in the subcutaneous fat by anagen VI. In the mouse, dermal adipocyte precursors secrete platelet-derived growth factor-A (PDGF-A), which acts on the dermal papilla to support anagen[67].

In rodents and rabbits, plucking telogen hairs can accelerate onset of the next anagen phase. The trauma of plucking causes release of chemokine C-C motif ligand 2 (CCL2) by the follicle, leading to recruitment of macrophages that secrete tumor necrosis factor (TNF), which promotes local follicles to enter anagen[68]. Osteopontin, which is produced by melanocytic nevi, also promotes anagen entry and stimulates hair growth[68a]. Other microenvironmental cues and "quorum-sensing" among HFs also likely play a role in hair cycle coordination.

FUNCTIONS OF HAIR AND NAILS
Functional properties of hair shafts
• Social and sexual communication • Camouflage • Protection against chemical and physical damage • Protection against insects • Provide sensory "antennae" • Insulation against heat loss, overheating, and desiccation • Removal from the skin surface of parasites, dirt, debris, and squames by the outward-moving hair shaft • Facilitation of sebum, apocrine sweat, and pheromone secretion • Organ of scavenging and excretion via the melanized hair shaft, which serves to deposit and extradite unwanted molecules • Hair shaft medulla can serve as a fiberoptic device for conversion of UV light into heat (polar bear)
Functional properties of pilosebaceous units
• Production, extrusion, containment, and mooring of pigmented hair shafts • Crucial stem cell reservoir, e.g. for keratinocytes and melanocytes • Reservoir for Langerhans cells • Highly sensitive tactile organs that sense hair shaft movements • Generate sebum, apocrine sweat, and pheromones
Functional properties of nails
• Social and sexual communication (color, shape, length) and aesthetic appearance • Protection of the distal phalanges of the digits from mechanical, chemical, and biological trauma • Contribute to the tactile discrimination and fine motor capacities of the fingertips • Provide the ability to scratch and groom • Rudimentary natural weapons • Contribute to pedal biomechanics essential for full motor functioning of the feet

Table 68.2 Functions of hair and nails. *Courtesy John P. Sundberg, DVM, PhD.*

Catagen

At the end of anagen, the follicle enters the regressive catagen phase, which is divided into eight substages (catagen I–VIII)[69]. Catagen lasts ~2 weeks in humans, regardless of the site and follicle type[61]. The initiation of catagen is characterized by a nearly 50% reduction in the volume of the dermal papilla due to loss of ECM and migration of cells into the surrounding dermal sheath, which acts as a repository that replenishes the dermal papilla in the subsequent anagen[70]. Melanocytes in the hair bulb also downregulate melanogenesis. Later, there is cessation of mitotic activity within the matrix cells of the bulb, and the remaining hair precursor cells at the base of the shaft differentiate to form a "club fiber".

The club fiber migrates up the follicle, and a germ capsule termed the trichilemmal sac forms around its base. This club fiber lacks pigmentation and is formed from cortical and cuticle cells only. The electron-dense, non-nucleated layer of trichilemmal keratin around its base has a characteristic "brush" structure that protrudes outwards and between surrounding ORS cells[71]. Abundant desmosomes between the trichilemmal keratin and surrounding tissue are thought to physically anchor the club fiber within its trichilemmal sac until it receives the signal for release[72].

As the club fiber moves up the follicle, the dermal papilla, which is initially still in the subcutaneous fat, becomes separated from the club by an epithelial strand that is surrounded by basement membrane (the glassy membrane)[73]. Apoptosis in the epithelial strand creates an "apoptotic force" that draws the dermal papilla up to just beneath the club fiber in the dermis, leaving behind a trailing dermal sheath called a fibrous streamer or stele[59]. FGF-5 produced by macrophage-like cells facilitates regression of human HFs[74], and *FGF5* mutations underlie familial trichomegaly characterized by abnormally long eyelashes[75]. Macrophages also participate in the clearance of cellular debris during catagen[76,77].

Loss-of-function mutations in the hairless gene (*HR*) can result in atrichia with papular lesions (APL)[78,79], a rare autosomal recessive disease characterized by complete hair loss early in life and later eruption of papular lesions. Hairless is a transcription factor that is required for apoptosis in the epithelial strand, which draws the dermal papilla up beneath the club fiber and secondary hair germ in a position to activate the next anagen phase. Thus, individuals with APL are born with hair, which never grows back after it is shed. Activating mutations in the upstream open reading frame of *HR* lead to another form of sparse hair, Marie Unna hypotrichosis[80]. Hairless interacts with the vitamin D receptor (VDR), which has ligand-independent functions in hair cycle control[81]. Patients with hereditary vitamin D-resistant rickets caused by *VDR* mutations present with alopecia that is not corrected by vitamin D supplementation[82].

Telogen

Telogen begins when the dermal papilla reaches the base of the permanent portion of the HF. The duration of telogen can be as short as 2 days in mice and as long as 3 months for human scalp hairs. The hair germ is derived from the bulge during the catagen-to-telogen transition and lies inferior to the bulge, separating the latter from the dermal papilla[83]. As in HF morphogenesis, epithelial–mesenchymal cross-talk is required to activate the new anagen phase. Anagen progression recapitulates the middle and later stages of HF development, and many factors that drive follicle morphogenesis (e.g. WNT, SHH, noggin) also play important roles in telogen-to-anagen transition (Fig. 68.4B). The

Downloaded for Anonymous User (n/a) at Egyptian Knowledge Bank from ClinicalKey.com by Elsevier on March 10, 2024. For personal use only. No other uses without permission. Copyright ©2024. Elsevier Inc. All rights reserved.

BASIC INFORMATION ON HUMAN HAIR FOLLICLES (HFs)	
Total number	~5 000 000 (mostly vellus)
Number of scalp HFs	~100 000 Blondes: + 20% Redheads: – 20%
Average density of hairs on the scalp*	Terminal + vellus: 1135/cm^2 (newborn) 615/cm^2 (20–30 years) 485/cm^2 (30–50 years) 435/cm^2 (70–80 years) African-Americans, Asians: lower density Terminal only: ~250/cm^2 Bald scalp (45–70 years): 330/cm^2 Highest density: cheek + forehead
Hair embryology	Development progresses at fixed intervals in cephalocaudal direction, first becoming visible in eyebrow, upper lip, and chin regions (9th week) At 16 weeks, hair shafts are formed in these regions HFs are formed in sequential waves of interspersed follicles
Hair cycle distribution for terminal scalp hair	Anagen: 85%–90% Telogen: 10%–15% Catagen: <1%
Duration of hair cycle phases	Anagen: 2–6 years Telogen: 2–3 weeks Catagen: 3 months } Terminal scalp hair
	There are substantial variations in anagen duration: Terminal mustache: 4–14 weeks Terminal on arms: 6–12 weeks Terminal on legs: 19–26 weeks Vellus: 6–12 weeks Premature anagen is induced by plucking of telogen hair shafts (depilation) Estrogens prolong anagen Thyroxine promotes growth, corticosteroids retard anagen onset
Number of lifetime cycles per scalp follicle	10–20
Physiologic hair shedding rate (scalp)	~100–200/day, with substantial interindividual and seasonal variations
Hair shaft production rate (scalp)	~0.35 mm/day, 1 cm/month Hair production is not influenced by cutting/shaving Estrogens reduce hair growth rate Androgens increase hair growth rate and hair diameter in androgen-dependent sites (e.g. beard)
Hair shaft diameter and length	Vellus: <0.03 mm; 1–2 mm Terminal: >0.06 mm; 1–50 cm Average diameter: Asian hair (circular): 120 microns Caucasian (elliptic): 50–90 microns
Hair shaft structures	Cuticle (outside), cortex, medulla (center) Cuticle maintains hair fiber integrity Cortex contains bulk of hair keratins and keratin-associated proteins Hair fiber strength is largely due to disulfide bonding Medulla consists of loosely connected trichocytes with large intercellular air spaces; provides insulation (animals)
Hair shaft pigmentation	Dark hair: predominance of eumelanin Blond/red hair: predominance of pheomelanin Melanosomes of hair cortex larger than those of epidermis
Hair graying (canities)	Generally commences in the third to fourth decade of life on the temples, spreading later to crown and occiput; by the age of 50 years, 50% of the population has at least 50% grey hair
Hair patterns	Pubic hair: horizontal (90% of women, 20% of men), acuminate (10% of women, 50% of men) Diffuse chest hair: normally grows only in men, after puberty until 6th decade Axillary: appears about 2 years after first pubic hairs, more sparse in Asians than White individuals; frequently absent in older individuals Trichoglyphics: single, clockwise parietal whirl present in 95% of individuals

*Data from Giacometti L. The anatomy of the human scalp. In: Montagna W (ed). Advances in Biology of Skin, Vol VI: Aging. Oxford: Pergamon Press, 1965:97–120.

Table 68.3 Basic information on human hair follicles (HFs).

bulge is relatively quiescent during telogen, traditionally referred to as the "resting" phase, due to inhibitory signals (e.g. FGF-18, BMP-6) from keratin 6-positive inner bulge cells[84]. The apparent dormancy of the HF during telogen may be an energy-efficient adaptation allowing for the maintenance of stem cells in preparation for the next anagen phase[85]. Consistent with this theory, mitochondrially localized myelin protein zero-like 3 (MPZL3) has recently been implicated in murine hair follicle cycling.[86]

The macro-environment surrounding the HF also takes part in regulating cycle transitions[87]. Immune cells surrounding the HF interact with the HF stem cell niche to control hair cycling. For example, in mice, TREM2$^+$ (triggering receptor expressed on myeloid

Downloaded for Anonymous User (n/a) at Egyptian Knowledge Bank from ClinicalKey.com by Elsevier on March 10, 2024. For personal use only. No other uses without permission. Copyright ©2024. Elsevier Inc. All rights reserved.

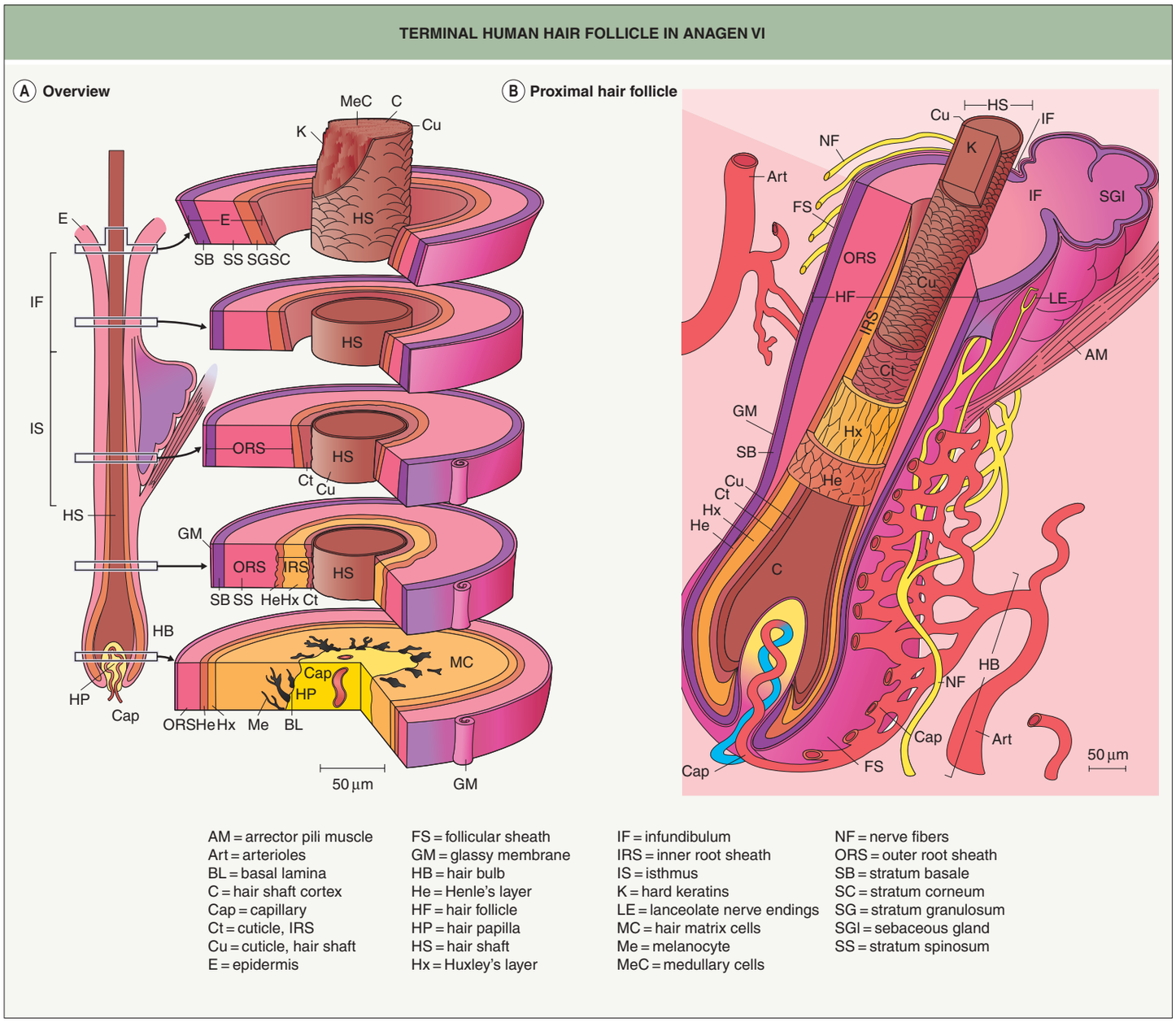

Fig. 68.5 Terminal human hair follicle in anagen VI. A Overview of the layers along the length of an anagen hair follicle. **B** Cross section of the longitudinal architecture of an anagen hair follicle.

cells 2) macrophages produce oncostatin M, which maintains the quiescence of HF stem cells and prevents anagen entry[88]. BMPs in the subcutaneous fat maintain HFs in a "refractory" telogen, and cessation of this inhibitory signal enables the follicle to progress to a "competent" telogen with a hair germ (biochemically distinct from the bulge) that is responsive to anagen-initiation signals and capable of entering a new anagen phase[83,89]. After secondary hair germ activation, the germ cells begin to contribute to the hair matrix and concentric layers of the follicle via an upward movement, while bulge cells generate the ORS through a downward movement[90]. In follicles with a longer anagen duration, the proliferative capacity of the matrix is not sufficient to sustain growth. The "stem cell trafficking theory" proposes that a continuous migration of precursor cells from the bulge down the ORS prevents exhaustion of the germinative matrix during anagen[91].

Exogen

The stimulus for entry into catagen, and hence the formation of a club hair, typically occurs several months before the hair is shed in humans[92]. "Exogen" represents the shedding of the club fiber (teloptosis) as well as the preceding signals and structural changes in the follicle[59]. Exogen is considered to be an active proteolytic event rather than a passive process where the club fiber is dislodged due solely to mechanical forces from the new growing fiber. A gradual decrease in the adhesion of the club fiber within its epithelial silo has been observed prior to its programmed release from the follicle[93].

Structure of the hair fiber

In response to signals from the dermal papilla, the matrix cells at the base of the follicle proliferate and differentiate during anagen, forming the layers of the follicle. The three central lineages – medulla, cortex, and hair cuticle – form the hair fiber, which fulfills the primary hair-producing function of the anagen follicle. Surrounding the hair fiber are the three concentric layers that compose the inner root sheath (IRS): the IRS cuticle, Huxley's layer, and Henle's layer. The IRS undergoes a complex program of differentiation during anagen, with Henle's layer terminally differentiating shortly after formation. The IRS cuticle differentiates further up the follicle, followed by Huxley's layer; all three layers undergo desmosomal remodeling during terminal differentiation[94]. The IRS forms a mechanically supportive tube around the hair fiber and is degraded by proteolytic enzymes at the level of the isthmus[95], allowing the hair shaft to enter the hair canal and emerge from the skin surface. Heparanase expressed in the IRS during anagen

Downloaded for Anonymous User (n/a) at Egyptian Knowledge Bank from ClinicalKey.com by Elsevier on March 10, 2024. For personal use only. No other uses without permission. Copyright ©2024. Elsevier Inc. All rights reserved.

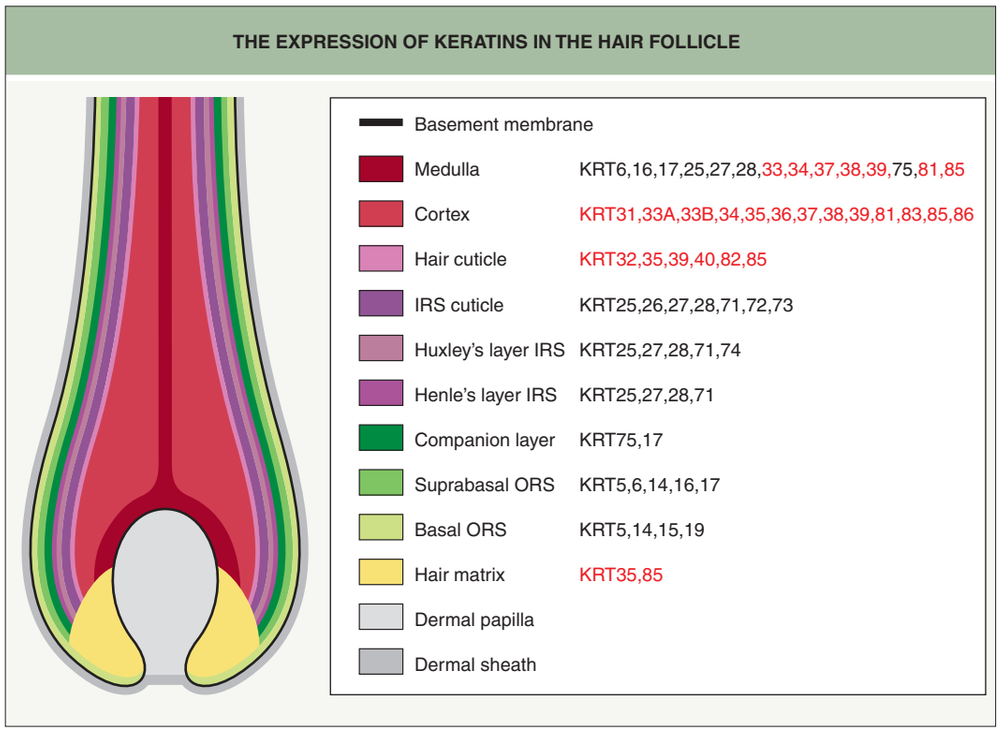

Fig. 68.6 The expression of keratins in the hair follicle. Hair keratins are in red font. KRT, keratin.

acts on heparin sulfate proteoglycans and controls IRS differentiation by influencing growth factor sequestration and diffusion[96].

The seventh concentric layer that originates from the matrix in line with the hair fiber and IRS is the companion layer, which is a single cell thick. Regarded as the "slippage plane" between the IRS and the surrounding ORS during anagen, the companion layer enables directional hair growth. It is attached to the IRS through "Flugelzellen" structures that extend from Huxley's layer through Henle's layer and link to the companion layer via numerous desmosomes[97,98]. A "barrel" of transversely oriented intermediate filaments on the inner side of the companion layer are thought to provide support for the inner root sheath, protecting it from the compressive forces of the expanding ORS[99].

Hair Keratins

The 54 functional keratin genes encode 28 type I and 26 type II keratins, which form heterodimeric pairs containing one keratin of each type[100]. There are 11 type I hair keratins, designated KRT31–KRT40, and six type II hair keratins, designated KRT81–KRT86 (see Table 56.2); the remainder are epithelial keratins[101,102]. Compared to epithelial keratins, hair keratins possess more sulfur in their head and tail domains, which allows them to form tight cross-links via disulfide bonds.

Different hair and epithelial keratins are expressed in the concentric layers of the HF, with hair keratins found primarily in the cortex and hair cuticle (see Fig. 56.6)[103]. Autosomal dominant monilethrix, which features fragile "beaded" hairs and follicular hyperkeratosis, is caused by mutations in the helix termination and initiation motifs of several type II hair keratins: KRT81, KRT86, and (less commonly) KRT83[104,105]. These keratins are highly expressed within the hair cortex and are critical to its development[104,105]. Mutations in the genes encoding KRT85 and KRT74 (see below) underlie autosomal recessive pure hair and nail ectodermal dysplasia. KRT85 is primarily expressed in the matrix of the follicle, which explains the total alopecia observed in these patients[106].

Some epithelial keratins exhibit HF specificity (see Fig. 68.6). The type I keratins KRT25, KRT27, and KRT28 and the type II keratin KRT71 are expressed within the IRS (cuticle, Huxley's layer, and Henle's layer). KRT74 is restricted to Huxley's layer, while KRT72 and KRT73 are found in the IRS cuticle[107]. Mutations in the genes encoding KRT71 and KRT74 can cause autosomal dominant woolly hair with or (for KRT74) without associated hypotrichosis[108,109], and a homozygous missense variant in *KRT25* has been implicated in autosomal recessive woolly hair[110].

The companion layer contains only one type II keratin, the epithelial KRT75, which is also expressed in the medulla of the hair shaft and the fungiform papillae of the tongue. Pseudofolliculitis barbae and loose anagen hair syndrome have possible links to defects in KRT75 in some patients[101]; KRT75 polymorphisms are also associated with reduced enamel hardness and increased risk of dental caries, highlighting the link between tooth and hair architecture[111]. The ORS expresses several keratins, including KRT5/KRT14, KRT6a/KRT16, and KRT6b/KRT17 (see Fig. 68.6). However, patients with pachyonychia congenita due to mutations in the latter keratin pairs only occasionally exhibit hair abnormalities such as pili torti (primarily with KRT17 defects)[112].

Desmosomes in the Hair Follicle

Desmosomes are specialized adhesive structures that couple neighboring cells together in a variety of tissues, with particular importance in epithelia and the myocardium[113]. Each desmosome is connected to the intermediate filament cytoskeletons of the interacting cells, which imparts resilience and resistance to mechanical stress (see Fig. 56.8). Desmogleins (Dsg1–4) and desmocollins (Dsc1–3) are desmosome-specific cadherins that interact in the intercellular space to couple the two halves of the desmosome; they are connected to intermediate filaments via the linker proteins plakoglobin, plakophilins (Pkp1–3), and desmoplakin. Mutations in genes encoding desmosomal components can result in diseases affecting: (1) the hair – woolly, fragile, and/or sparse; (2) the skin – palmoplantar keratoderma, fragility/blistering; and (3) the heart – cardiomyopathy. This leads to multisystem disorders such as Naxos disease, Carvajal syndrome, and skin fragility–ectodermal dysplasia syndrome (see Fig. 56.8 and Ch. 58).

All four desmogleins are found in the HF, with differentiation-specific expression patterns[114,115]. Dsg4 is the only desmosomal cadherin that is highly expressed in the hair shaft cortex, including the keratinizing zone in which hair keratins are abundant. Dsg4 is also present in the precortex, lower hair cuticle, upper IRS cuticle, and interfollicular epidermis (granular and cornified layers)[116]. Transcription factors that regulate the expression of both Dsg4 and hair keratins in differentiating trichocytes include LEF1 (lymphoid enhancer-binding factor), HOXC13 (homeobox C13), and FOXN1 (forkhead box N1)[117]. Dsg4 is a key mediator of keratinocyte adhesion in the HF, where it coordinates the transition from proliferation to differentiation[116]. Mutations in *DSG4* can cause autosomal recessive forms of localized hypotrichosis and monilethrix, with the pathomechanism involving a stress response due to accumulation of the mutant protein in the endoplasmic reticulum (ER)[118].

Downloaded for Anonymous User (n/a) at Egyptian Knowledge Bank from ClinicalKey.com by Elsevier on March 10, 2024. For personal use only. No other uses without permission. Copyright ©2024. Elsevier Inc. All rights reserved.

Although hair shedding and alopecia result when Dsg3 is disrupted in mice[119,120], similar hair phenotypes have not been identified in humans with Dsg3 defects. However, a homozygous mutation in *DSC3* has been reported to underlie hypotrichosis with recurrent skin "vesicles"[121]. In addition, mutations in *CDSN* which encodes corneodesmosin, a glycoprotein found in the IRS and modified desmosomes within the stratum corneum, can result in autosomal dominant hypotrichosis simplex of the scalp (see Fig. 56.8)[122]. *CDSN* mutations also cause autosomal recessive inflammatory peeling skin syndrome, reflecting the role of corneodesmosin proteolysis in desquamation[123].

Hair Follicle Stem Cells

Adult stem cells have the ability to self-renew and to regenerate tissues during homeostasis and wound repair. Given the dynamic remodeling seen with the cyclic regeneration of the HF, it has long been postulated that it contains one or more stem cell niche(s) (see Ch. 2). Studies in the 1990s showed that slow-cycling, label-retaining cells (characteristics of stem cells) are localized within the HF bulge area, which is named for the swelling evident at this site in rodents[66].

Although the bulge architecture in mice is not pronounced until 3 weeks after birth, slow-cycling bulge cells can be identified during early stages of murine HF morphogenesis by the marker SOX9[124]. During anagen in adult mouse skin, bulge stem cells express distinctive markers, including SOX9 as well as S100A4 and CD34. The molecular architecture of the bulge is not identical in mice and humans, as the human HF stem cell niche is not morphologically distinct. However, analysis of human anagen HFs have identified distinctive human bulge cells with clonogenic potential that express CD200 but, in contrast to bulge cells in mice, not CD34 (see Table 2.2)[125].

When murine follicles cycle through telogen, a secondary hair germ is formed below the bulge, just above the dermal papilla. Bulge cell progeny in this hair germ that had migrated out of the stem cell niche during the previous anagen are capable of returning and regaining stem cell characteristics[84]. Some markers are expressed in both the secondary hair germ and the bulge, including keratin 15 and (at low levels) SOX9[83] while others are only highly expressed in the former (e.g. P-cadherin, LEF1)[83]. Following wounding, bulge and hair germ cells can both contribute to the interfollicular epidermis[126]; however, this does not occur under homeostatic conditions. Cell populations that maintain the sebaceous glands and interfollicular epidermis in mice include a LGR6 (leucine protein G rich repeat coupled receptor 6)-positive population in the central isthmus[127] as well as leucine-rich repeats and LRIG1 (immunoglobulin-like domains 1)- and Blimp1-positive populations in the upper isthmus[128,129]. There is also an SCA1 (stem cell antigen-1)-positive cell population in the infundibulum that is thought to contribute to skin homeostasis[130].

The dermal papilla and dermal sheath represent a mesenchymal stem cell niche within the follicle. Under homeostatic conditions, dermal papilla cells rarely divide after formation of the initial condensate during morphogenesis, yet their gene expression profile is dynamic throughout development and the hair cycle. If removed from their niche, dermal papilla cells have the ability to differentiate into osteogenic, myogenic, adipogenic, and hematopoietic lineages[131–133]. In addition to their ability to transdifferentiate, a major function of dermal papilla cells is related to their inductive potential. Isolated and cultured dermal cells from adult follicles are capable of stimulating a range of committed epithelia to form follicles, inclusive of progenitor stem cells[55,134–136]. The potential of cultured human dermal papilla cells to induce *de novo* hair growth provides the basis for novel therapeutic approaches[56].

The Hair Follicle and the Immune System

The HF represents an immune privileged site, which is defined as a location in the body where foreign tissue grafts can survive for extended periods of time without immune rejection. Of note, other immune privileged sites include the anterior chamber of the eye, testis, brain, and placenta.

Initial evidence regarding the immune protection of the HF came from the classic "Billingham experiment" in 1971[137], in which skin from black guinea pigs was transplanted onto an immunologically incompatible strain of white guinea pigs. The grafted skin turned white, reflecting the expected immune response against the foreign epidermal melanocytes. However, pigmented hairs grew within the grafts, showing that the foreign HF melanocytes survived. Application of the contact allergen picryl chloride to mouse skin during early anagen results in an attenuated sensitization reaction compared to application during telogen[138], suggesting that the HF immune system is suppressed specifically during anagen. Features of the human anagen hair bulb that protect it from an immune response are summarized in Table 68.4.

The immune privilege of the HF was previously thought to be restricted to the matrix region during the anagen phase. However, evidence has accumulated that the bulge region has immune privilege during the entire hair cycle[139]. Since the bulge represents the HF stem cell niche, sustained immune privilege in this region may be essential for the survival of the follicle. Autoimmune attack leading to loss of the stem cells in the bulge results in cicatricial alopecia where regrowth is unlikely[140].

Two mechanisms can potentially underlie an immune reaction directed against the hair: (1) a primary attack of the immune system against the HF; or (2) a breakdown in HF immune privilege leading to a secondary attack by the immune system[141–143]. Since the hair matrix immune privilege is mainly restricted to the anagen phase[143], it has been postulated that an autoantigen from melanocytes, which are active during the anagen phase, could be responsible for initiating the immune response against the HF that occurs in alopecia areata. Indeed, antibodies against melanocyte-associated antigens have been found in patients with this condition[144,145].

The collapse of HF immune privilege is linked to upregulation of HF major histocompatibility complex (MHC) class I molecule expression, which allows presentation of autoantigens to the immune system[146]. In HFs affected by alopecia areata, there is increased expression of MICA (MHC class I polypeptide-related sequence A). $CD8^+$ T cells and natural killer (NK) cells accumulate around affected HFs and exhibit increased expression of the NKG2D activating receptor, but decreased expression of inhibitory receptors such as KIR3DL1 (killer cell

MECHANISMS CONTRIBUTING TO THE IMMUNE PRIVILEGE OF THE HAIR FOLLICLE	
Mechanism of immune evasion	**Function of the molecules affected**
Downregulated expression of MHC class I, MICA, and β_2-microglobulin	Required for presentation of autoantigens to the immune system
Downregulated expression of MHC class II	Required for functioning of antigen-presenting cells
Upregulated expression of IL-10, transforming growth factor-β1 (TGF-β1), and α-melanocyte stimulating hormone (α-MSH)	Immunosuppressive actions
Increased production of Fas-ligand (FasL)	Induces apoptosis of activated T cells; known to be crucial for maintenance of immune privilege in the eye, brain, and fetus
Low expression of heterodimeric CD94/NKG2C and NKG2D receptors on NK cells and $CD8^+$ cytotoxic T cells as well as of the NKG2D ligand UL16 binding protein 3 (ULBP3)	These receptors activate NK cells and $CD8^+$ cytotoxic T cells upon ligand binding; NKG2D has been implicated in the immune attack on the hair follicle in alopecia areata
High expression of killer cell immunoglobulin-like receptors (KIRs) and heterodimeric CD94/NKG2A receptors on NK cells	These receptors inhibit NK cells
Increased production of indoleamine 2,3-dioxygenase (IDO)-1	Inhibits lymphocyte proliferation
Increased production of IK cytokine	Inhibits interferon-γ-induced expression of MHC class II antigens
Lack of lymphatic vessels around the hair follicle	Recruit immune cells

Table 68.4 Mechanisms contributing to the immune privilege of the hair follicle. IL, interleukin; MHC, major histocompatibility complex; MICA, MHC class I polypeptide-related sequence A; NK, natural killer.

Downloaded for Anonymous User (n/a) at Egyptian Knowledge Bank from ClinicalKey.com by Elsevier on March 10, 2024. For personal use only. No other uses without permission. Copyright ©2024. Elsevier Inc. All rights reserved.

immunoglobulin-like receptor three domains long cytoplasmic tail 1) and heterodimeric CD94/NKG2A[143,147]. ULBP3 (UL16 binding protein 3), a NKG2D ligand, is upregulated in the dermal sheath and papilla of HFs affected by alopecia areata[147]. These observations indicate that HFs in patients with alopecia areata lose their immune privilege and express danger signals in their outermost layer.

The pathogenesis of alopecia areata also involves downregulation of immunosuppressant molecules such as transforming growth factor (TGF)-β1, α-melanocyte stimulating hormone (MSH), indoleamine 2,3-dioxygenase (IDO)-1, and the IK cytokine that inhibits the functions of interferon (IFN)-γ[139,141,143]. IFN-γ plays a pivotal role by inducing the expression of MHC class II antigens, which are normally absent in the HF matrix and dermal sheath, thereby propagating the immune response and contributing to destruction of the hair follicle.

Genome-wide association studies (GWAS) in patients with alopecia areata have implicated genes that are involved in immune regulation, in particular the function of regulatory T cells, such as cytotoxic T lymphocyte-associated protein 4 (CTLA-4), interleukin (ILs)-2 and -21, the IL-2 receptor A (CD25), ULBPs, and Eos (an Ikaros transcription factor), as well as genes expressed in the follicle (e.g. syntaxin 17, peroxiredoxin 5)[147,148]. Such studies have provided insights into potential therapeutic targets. For example, treatment with inhibitors of the Janus kinase (JAK) pathway, which is involved in signaling by many of the cytokines implicated in alopecia areata, can result in significant hair regrowth[149,150].

BIOLOGY OF NAILS

Like its phylogenetic ancestors (e.g. claws, hoofs), the nail protects the distal phalanges and contributes to a variety of motor and sensory functions (see Table 68.2). Two key aspects of nail biology are how nails grow and from what part of the nail apparatus they arise. The composition and appearance of the nails and the characteristics of the surrounding tissues are other important considerations, potentially representing signs of internal disease or environmental exposures[151,152]. An understanding of these aspects of the nail unit, in addition to its anatomy and development, can maximize the clinician's ability to assess, diagnose, and treat patients with nail disorders. However, our current knowledge of the regulation of nail development and growth on a molecular level is relatively poor, and acquisition of data has been hampered by the difficulty in obtaining nail-producing tissues and growing nails and/or nail matrix keratinocytes in culture. Tools such as mouse models given the substantial homology between murine claws and human nails, organ-culturing microdissected components of the human nail apparatus, and nail-equivalent *in vitro* systems will hopefully help to better elucidate the molecular mechanisms of nail biology.

Nail Unit Anatomy

An understanding of nail biology and disease requires knowledge of the local anatomy (Fig. 68.7)[153,154]. The nail plate is a hard, semitransparent, slightly convex sheet comprised of tightly packed corneocytes termed onychocytes. It contains "hard" hair-type keratins, which are embedded in a matrix of sulfur-rich, high-cysteine and high-glycine/tyrosine proteins (see below). The dermis of the nail apparatus is a fibrocollagenous network that is sandwiched between the nail plate and the underlying bone, lacking associated subcutaneous soft tissues or pilosebaceous units. As a result, bacterial infections in this region have a relatively high risk of spread to the bone, resulting in osteomyelitis of the distal phalanx.

The nail plate is surrounded on three edges by nail folds, one proximal and two lateral. The proximal nail fold, a double layer of skin overlying the proximal part of the nail, protects this area from trauma, solvents, and infectious agents that might otherwise alter nail shape and structure. The dorsal layer of the proximal nail fold is continuous with the skin of the digit, while the ventral layer is continuous with the nail matrix. The cuticle (eponychium) is a thin strip of cornified epithelium that adheres to the nail at the edge of the proximal nail fold and acts as a seal against ingress. Damage to the cuticle results in a predisposition to inflammation of the nail fold; conversely, inflammation of the nail folds disrupts normal maturation of the epithelium and cuticle formation. Nail-fold inflammation can also disturb the underlying matrix and alter nail plate production, most often manifesting as transverse ridging. The proximal nail fold may help to mold the emerging nail, forming a relatively thin structure that grows obliquely from its point of origin in the matrix.

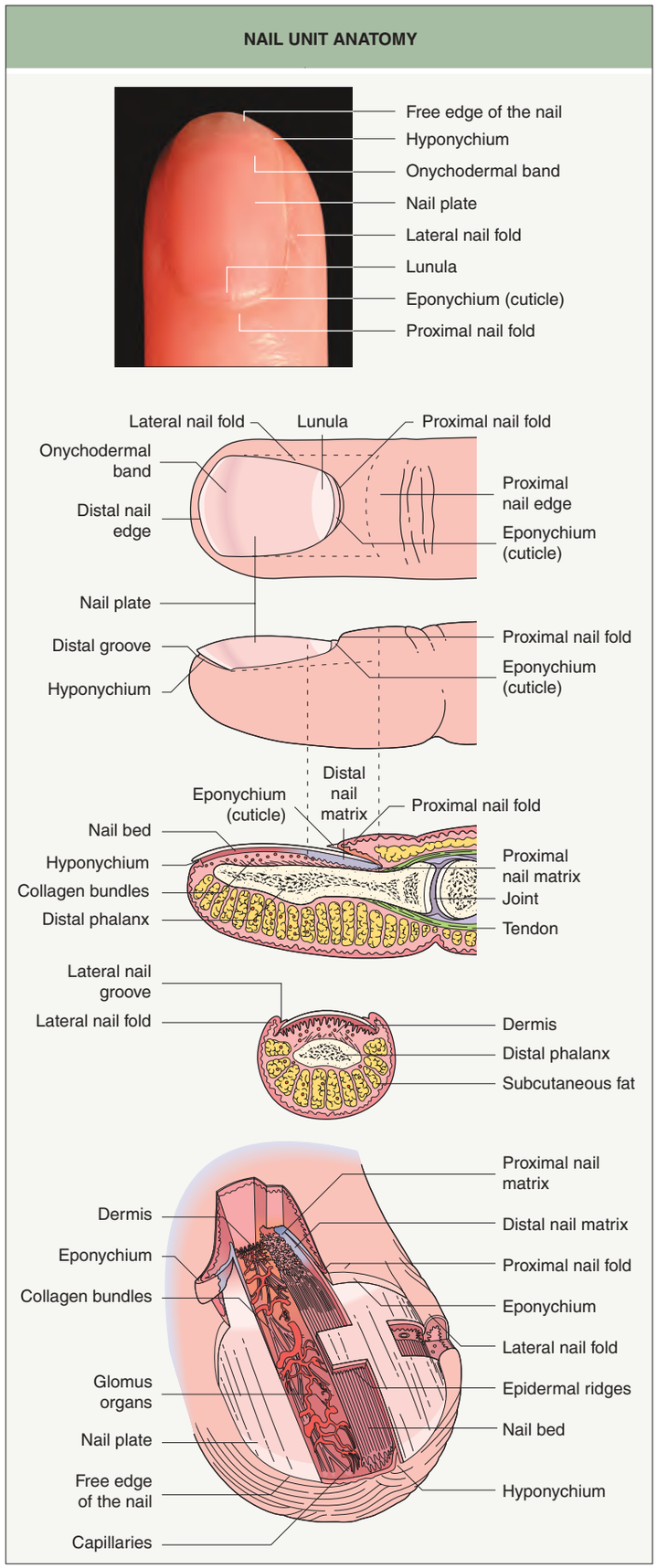

Fig. 68.7 Nail unit anatomy.

The longitudinal axis of nail growth is also guided by the lateral nail folds, which compress the nail plate from each side and contribute to its transverse curvature. The lateral margins of the nail bed form deep

Downloaded for Anonymous User (n/a) at Egyptian Knowledge Bank from ClinicalKey.com by Elsevier on March 10, 2024. For personal use only. No other uses without permission. Copyright ©2024. Elsevier Inc. All rights reserved.

sulci that follow the curve of the distal phalanx and then fold back on themselves to produce the lateral nail folds. These sulci help to attach the nail to the soft tissues and, similar to the proximal nail fold and cuticle, provide a seal at the nail margin.

The structures bounded by the nail folds are the nail matrix proximally and the nail bed distally and medially. The half-moon-shaped lunula, which is most prominent on the thumb, demarcates the junction between the matrix and the nail bed. The lunula is less apparent, due in part to concealment by the proximal nail fold, with progression from the second to fifth finger. The lunulae of the toes are hidden by their thicker nail plates (especially for the great toes) and relatively prominent proximal nail folds, which may serve a protective function[153,154].

The nail plate is in continuity with the matrix from which it arises, while the nail bed represents its underlying support structure and extends from the distal margin of the lunula to the onychodermal band, a thin pinkish transverse strip proximal to the whitish onychocorneal band (see Fig. 68.7). A longitudinal pattern of rugose rete ridges in the nail bed increases the surface area of its attachment to the ventral aspect of the nail, which has corresponding ridges. This enhances adhesion between these surfaces and enables the free edge of the nail to be used as a levering tool without lifting the nail or causing pain. Histologically, both the nail bed and matrix normally lack a granular layer. The presence of a granular layer in these sites is a sign of pathology, such as the altered nail bed behavior associated with subungual hyperkeratosis.

The nail is in close proximity to the underlying distal phalanx, and BMPs are thought to have roles in the morphogenesis of both structures. When the distal phalanx and/or interphalangeal joint are affected by an inflammatory disease such as psoriasis, involvement of the nail matrix (and hence nail plate) often occurs. Congenital absence of part of the distal phalanx is typically accompanied by a small or otherwise altered nail (e.g. congenital onychodysplasia of the index fingers), further illustrating the relationship between these two structures[155]. In the neonatal period, digit tip regeneration can occur in humans after partial amputation. This appears to require the presence of a residual nail unit and to involve the expression of BMP-4 and the MSX1 (muscle segment homeobox 1) transcriptional repressor[156]. Overexpression of MSX1 and MSX2 is associated with increased regenerative capacity[157]. There appears to be a reciprocal interaction between nail and bone, with bone mesenchyme providing a scaffold for nail regrowth and the nail bed facilitating regeneration of underlying bone[158,159]. In later life, regeneration rarely, if ever, occurs upon partial amputation of the fingertip due to trauma or osteolysis in the setting of scleroderma, and secondary nail changes typically ensue.

Studies in adult mice suggest that LGR6-expressing nail stem cells in the proximal matrix are capable of WNT-dependent nail blastema formation, which enables digit tip regeneration[160,161]. Nerve-associated Schwann cell precursors that dedifferentiate and secrete growth factors such as oncostatin M and platelet-derived growth factor A promote expansion of the blastema and are required for murine digit regeneration[162]. The cytoskeletal protein flightless I (Flii) also enhances murine digit regeneration after amputation; although this is normally limited to distal third amputations, mice with overexpression of Flii can retain the proximal nail matrix and regenerate proximal amputations[163]. Outside of the nail unit Flii is associated with *inhibition* of epidermal stem cells and wound reepithelialization[164], suggesting that prevention of epithelialization may allow continued connective tissue proliferation and thereby enable the subepidermal repair required for greater digit regeneration. These observations in mice may help to develop therapies for human amputees in the future.

The vascular supply of the digit is through two dorsolateral and two ventrolateral arteries that lack an internal elastic lamina and have a tortuous morphology that helps them to withstand flexion and other movements. There is substantial communication between these vascular networks, particularly distally via plexuses in the proximal nail fold and digital pulp. This provides the digit with a blood supply of more than one origin and direction, which ensures continued flow in the event of trauma or a sustained grip that decreases supply from the ventral vessels. The pulp plexus is located within a recess produced by the gap between the ventral prominence of the distal phalanx and the rim of the distal interphalangeal joint[165].

In a cold environment, which leads to constriction of arterioles, arteriovenous anastomoses (Sucquet–Hoyer canals) within glomus bodies maintain sufficient blood supply to the distal digits. Glomus bodies are encapsulated oval structures containing modified smooth muscle cells that dilate upon exposure to the cold. These structures are most prominent in the subungual tissue, which represents the most common site of a glomus tumor, a benign proliferation of glomus cells[166] (see Ch. 114).

In the proximal nail fold, the dermal capillaries normally form a regular pattern of "hairpin" loops with a thin efferent limb and a more tortuous, thicker afferent limb. The organization of nail bed vessels is similar, although the hairpin turn is less evident. Dermatoscopic examination (capillaroscopy) of nail-fold vessels can help to assess a patient's acral microvascular status. The pattern and/or patency of the capillaries in the proximal nail fold and nail bed is often altered in patients with an autoimmune connective tissue disease (AI-CTD) or embolic disorder. The proximal nail folds of patients with lupus erythematosus typically show dilated, tortuous capillaries of normal density, whereas systemic sclerosis and dermatomyositis feature hemorrhages and decreased capillary density characterized by avascular areas alternating with dilated capillary loops. Acral infarction due to embolization (e.g. in the setting of endocarditis) can result in leakage of blood into the nail bed, referred to as splinter hemorrhages. These lesions can also develop secondary to trauma, AI-CTD, and psoriasis; the latter condition is associated with an increased number of papillary dermal vessels, disrupted nail integrity, and shearing forces between the nail plate and bed.

The nerve supply of the digit follows the pattern of the vascular supply, with two dorsal and two ventral branches that have some overlap distally in their sensory territories[154]. Since the fingertips have an important role in sensory perception, nerve endings that transmit pain (type I fibers), touch (Meissner and Pacinian bodies), and temperature are all abundant. The function of these nerve endings may be compromised by pressure due to relatively minor trauma and edema within the fascial envelope that encloses a finger or toe.

Nail Embryology

The nail primordium becomes evident at 8 weeks' gestational age as a transverse ridge on the distal dorsal surface of the digit (Fig. 68.8) (see Ch. 2). Over the next 4 weeks, the ridge takes a more proximal position and eventually invaginates beneath the emerging proximal nail fold. The outline of the nail unit is established by 16 weeks' gestational age, and the nail plate completely covers the nail bed during the fifth month.

The study of inherited nail diseases has provided clues regarding some of the processes that regulate the formation of the nail unit. An autosomal recessive form of anonychia congenita is caused by loss-of-function mutations in the gene encoding R-spondin 4 (RSPO4), which functions in the WNT signaling pathway[167]. Mouse studies have demonstrated expression of *Rspo4* in digit mesenchyme during embryogenesis, and it is thought to influence induction of the nail unit in the overlying epithelium. Human *WNT10A* mutations that alter β-catenin signaling can result in nail dystrophy as well as hypotrichosis, hypodontia, and palmoplantar keratoderma (see Ch. 63)[168]. In contrast, changes in claw formation have not been noted in *Wnt10* knock-out mice[169].

Nail–patella syndrome is another genetic disorder that has contributed to our understanding of nail development. The nail changes in this autosomal dominant condition include triangular lunulae and absent or hypoplastic nails, with most prominent involvement of the thumbnail and other radial digits; however, an individual nail is usually more severely affected on its ulnar side. Extracutaneous manifestations include hypoplastic patellae, iliac horns, nephropathy, and glaucoma. Nail–patella syndrome is caused by mutations in the gene encoding the LIM homeobox transcription factor 1β (LMX1B), which influences dorsoventral limb patterning[170,171]. In Clouston syndrome, a form of ectodermal dysplasia due to mutations in the gap junction β6 gene (*GJB6*) that encodes connexin 30, thickened nails with onycholysis occur in association with hypotrichosis and palmoplantar keratoderma (see Ch. 63)[172]. These genetic nail diseases illustrate the importance of communication between cells and tissues in the morphogenesis of the nails as well as other adnexal structures and organs. These messaging systems use the same code to initiate a variety of events in different tissues. Other genetic diseases affect the nails through alteration of their structural components, such as keratins or constituents of the basement membrane.

Downloaded for Anonymous User (n/a) at Egyptian Knowledge Bank from ClinicalKey.com by Elsevier on March 10, 2024. For personal use only. No other uses without permission. Copyright ©2024. Elsevier Inc. All rights reserved.

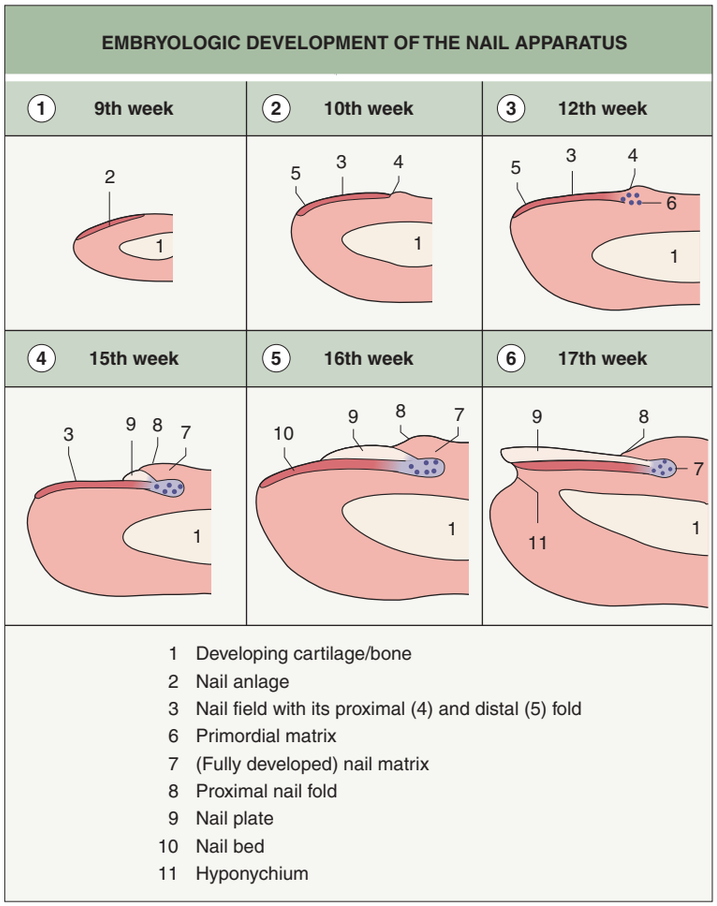

Fig. 68.8 Embryologic development of the nail apparatus.

Fig. 68.9 Nail matrix biopsy to determine the etiology of longitudinal melanonychia. Note that the pigment in the nail extends to the proximal part of the matrix in the nail plate and (as seen when the nail is lifted) the matrix itself.

Nail Matrix

"Nail matrix" is a functional and anatomical term; although there is currently general consensus with regard to these definitions, disagreement about the precise functional role of the matrix (see below) can potentially lead to confusion about its exact anatomy.

Matrix anatomy

The anatomical boundaries of the classical matrix are visible during a surgical procedure in which the nail is avulsed and the proximal nail fold retracted (Fig. 68.9). This reveals two zones of tissues on which the nail rests, a proximal pale nail matrix and a distal pinker nail bed. Their arcuate junction is evident through the nail plate as the lunula (half moon). The most lateral portion of the matrix may be "buried" in the sulcus of the lateral nail fold (see Fig. 149.2); because this can be difficult to access surgically, procedures designed to remove the lateral part of the nail matrix sometimes leave behind a small piece of matrix that produces a detached spicule of nail (see Fig. 149.15). Proximally, the matrix extends to the point of flexure of the proximal nail fold, where the latter structure turns back over and protects the proximal margin of the nail (see Fig. 68.7). Compared to epidermal keratinocytes, those in the nail matrix are larger and have a higher rate of proliferation.

Matrix function

For more than 50 years, anatomists and clinical scientists have investigated the relationship between the matrix and production of the nail (Fig. 68.10). Early work by Lewis[173] used static histology of silver-stained longitudinal sections of the nail unit to delineate three layers that he postulated were derived from separate epithelial surfaces within the nail unit: (1) the ventral aspect of the proximal nail fold (upper nail plate); (2) the classical matrix as defined above (mid nail plate); and (3) the nail bed (lower nail plate). This led to the misconception that there are three areas of matrix – dorsal, ventral, and intermediate. Subsequent studies in squirrel monkeys, which have digits similar to those in humans, utilizing *in vivo* autoradiography provided evidence that most, if not all, of the nail plate is generated from the classical matrix[174]. In these experiments, systemic injection of tritiated thymidine was followed by amputations at different time points, demonstrating that the thymidine reached the nail plate via the matrix. Injection of radiolabeled glycine into the nail unit of human volunteers who then had nail biopsies also showed that the classical matrix is the main source of the nail plate[175].

In the early 1990s, Johnson and colleagues[176] found that between the distal margin of the lunula and the end of the nail bed, the nail plate of the great toe increases in thickness by ~20%. They inferred from this observation that the nail bed contributed this proportion of the nail plate. Histologic assessment of great toe nail plates obtained via avulsion confirmed this increase in thickness but showed that the number of cells in the vertical axis of the nail plate did not increase from the proximal to distal nail bed. These results suggested that the nail plate thickens because of compaction due to distal-to-proximal compression rather than an active contribution from the underlying nail bed[177]. Walking while wearing shoes produces low-grade, repetitive trauma to the free edge of the great toenail, which would explain such an effect[177].

Immunohistochemical staining with proliferating cell nuclear antigen or Ki-67 demonstrates minimal proliferative activity in the nail bed but substantial activity in the matrix, further supporting that the matrix is the source of the nail plate[178]. The correlation between anatomy and function explains the different patterns of nail disease that result from pathology affecting the matrix versus the nail bed (see Table 71.1). It also accounts for the potential for permanent nail deformity following surgical intervention or biopsy of the matrix, but not for similar interventions involving the nail bed. Because the proximal half of the matrix produces ~80% of the nail plate, surgeries or biopsies in this area are more likely to produce nail dystrophy than those of the distal matrix. Onychocytes migrate upward and distally along an oblique axis during their maturation and differentiation; as a result, the proximal part of the matrix produces the dorsal portion of the nail plate, while the distal part of the matrix synthesizes the ventral portion of the nail plate. Abnormalities in the proximal matrix underlie clinical findings such as pitting and longitudinal ridging/splitting, whereas disruption of the distal matrix can cause true leukonychia. Interestingly, nail pitting can occur in association with alopecia areata, suggesting shared pathomechanisms.

Nail Stem Cells

Identification of label-retaining cells in the basal layer of the nail matrix has suggested that this represents the main source of nail stem cells[179], although other experimental approaches have suggested alternative nail stem cell niches[180]. In labeling studies, basal cells from the proximal nail matrix persisted longer than those from the distal matrix or nail bed[160]. Lineage tracing using HF stem cell markers (e.g. KRT15)

Downloaded for Anonymous User (n/a) at Egyptian Knowledge Bank from ClinicalKey.com by Elsevier on March 10, 2024. For personal use only. No other uses without permission. Copyright ©2024. Elsevier Inc. All rights reserved.

THEORIES ON THE ORIGIN OF THE NAIL PLATE

Origin of the nail plate	Evidence	Schematic, reference
Three portions of the nail matrix form three corresponding parts of the nail plate, which is characterized by a three-layer structure: Dorsal part = Proximal nail fold → Upper nail plate Inter-mediate part = Classical nail matrix → Intermediate nail plate Ventral part = Nail bed → Lower nail plate	Light microscopy and silver staining of human nails	Lewis (1954)
Cells of the classical matrix are the origin of the whole nail plate	*In vivo* auto-radiography (with tritiated thymidine) in squirrel monkeys	Zaias and Alvarez (1969)
Cells of the classical matrix produce nearly the total nail plate. Only a few cells of the nail bed in poorly defined locations take part in forming the nail plate	*In vivo* auto-radiography (with radiolabeled glycine) in human volunteers	Norton (1971)
The regrowth of nail plates following traumatic avulsion of great toenails was investigated: approximately 20% of the nail plate's thickness was added when the nail grew over the nail bed, suggesting a nail bed contribution to the nail plate's growth	Changes in nail plate's thickness during nail growth in human volunteers	Johnson et al. (1991,1993)
Cells of the proximal half of the matrix produce approximately 80% of the nail plate, whereas 1% or less of the nail plate is contributed by the nail bed. In psoriatic nails, the nail bed contribution may increase to over 25%	Immunohisto-chemical labeling in healthy human nails with antibodies to proliferating cell nuclear antigens and antigen Ki-67	Healthy nail Psoriatic nail de Berker and Angus (1996); de Berker et al. (1996)

Sites of origin and their contributions to the nail plate:

- Proximal matrix within nail fold (dorsal matrix)
- Nail bed
- Nail matrix
- Proximal half of nail matrix
- Distal half of nail matrix

Fig. 68.10 Theories on the origin of the nail plate. *Adapted fom Dawber RP, de Berker DA, Baran R. Science of the nail apparatus. In: Baran R, Dawber RP, de Berker DA, et al (eds). Diseases of the Nails and their Management. Oxford: Blackwell Science, 2001;1–47.*

identified a ring-like population of quiescent cells in the proximal nail fold that was harboring putative stem cells[181]. Much like the HF, the nail unit is likely to have more than one stem cell niche, each with distinct cellular dynamics and function.

Nail Unit Melanocytes

Melanocytes are found in the nail matrix but not in the normal nail bed. In general, foci of pigment in the nail bed that are separated from the nail folds and matrix are not melanocytic in origin[182], with possible exceptions including a metastatic melanoma and a partially amelanotic melanoma that is continuous with the matrix or nail fold. Nail matrix melanocytes are most abundant in the distal matrix and are found in suprabasal layers as well as the basal layer, which may reflect a distinct expression pattern of adhesion molecules (e.g. α_2, α_3, and β_1 integrins) that regulate interactions between melanocytes and keratinocytes[183].

The main distribution pattern of melanin in the nail plate is pigmented bands, referred to as longitudinal melanonychia, which vary in number, intensity, and width depending on their etiology (see Ch. 71). Multiple streaks of longitudinal melanonychia due to active nail matrix melanocytes are commonly found in individuals with darkly pigmented skin, sometimes as a result of trauma or inflammation affecting the matrix. In contrast, nail matrix melanocytes in individuals with lightly pigmented skin are normally quiescent; longitudinal melanonychia in such patients, especially an isolated band in an adult with no systemic or local causative factors, usually requires a nail matrix biopsy to exclude the possibility of melanoma (see Ch. 149). Inadequate biopsy specimens (e.g. too small, non-representative) can lead to a delay in diagnosis and less favorable prognosis[184].

The Nail Immune System

The nail unit, in particular the proximal matrix, represents a site of relative immune privilege, with reduced expression of MHC class I and II antigens and decreased numbers of antigen-presenting cells. Similar to the HF, the stem cell niche of the nail unit is believed to have immune privilege to ensure its preservation in the face of constant environmental exposure. Although the immune privilege may prevent over-reactivity to environmental antigens, it may also increase vulnerability to human papillomavirus infections and their potential oncogenic effects, which can result in periungual squamous cell carcinomas[185]. Collapse of immune privilege has been suggested to underlie lichen planus of the nail unit as well as lichen planopilaris of the scalp[140].

Nail Keratins

Multiple types of keratins are expressed in the nail apparatus (Fig. 68.11), and they account for 80% of the dry weight of the nail plate. The nail plate and matrix contain "hard" hair-type keratins with a large number of sulfur-containing amino acids that facilitate cross-linking between keratin molecules. This reduces the amount of water associated with these proteins and makes them more rugged and resistant to chemical destruction compared to "soft" epithelial keratins[186]. Keratin 15 in the proximal ventral aspect of the proximal nail fold may represent a marker of a keratinocyte stem cell population[181].

The pattern of keratin expression within the nail unit explains the involvement of this structure in several genodermatoses that are caused by keratin defects[187,188]. Pachyonychia congenita (PC) is an autosomal dominant disorder caused by mutations in the genes encoding keratins 6a, 6b, 6c, 16, or 17 (see Chs. 58 & 71). These keratins are expressed in the nail bed, HF, and sebaceous gland as well as palmoplantar, injured (e.g. ulcer margins), and hyperproliferative epidermis. PC features thickening of the nail plate, much of which represents compaction of dense subungual hyperkeratosis, together with painful palmoplantar keratoderma, follicular keratoses, and variable oral leukokeratosis and cysts (e.g. steatocystoma multiplex). Nail fragility as well as alopecia characterize the pure hair–nail ectodermal dysplasia that results from mutations in the gene for keratin 85. In these patients, keratin 85 lacks two cysteine residues, which may compromise nail integrity via diminished cross-linking of amino acids within keratins.

The nail bed does not express keratins 1 and 10[188], which characterize terminally differentiated stratified epithelia such as the epidermis. It has been postulated that the presence of the nail plate overlying the nail bed inhibits further differentiation of the latter structure. Indeed, if the nail plate is avulsed, the nail bed develops a cornified layer over the next 3 to 4 weeks.

Other Nail Plate Components

In addition to keratins, the nail plate contains structural proteins high in sulfur (with elevated cysteine content) or glycine and tyrosine

Downloaded for Anonymous User (n/a) at Egyptian Knowledge Bank from ClinicalKey.com by Elsevier on March 10, 2024. For personal use only. No other uses without permission. Copyright ©2024. Elsevier Inc. All rights reserved.

DISTRIBUTION OF KERATINS AND NON-KERATIN PROTEINS IN THE NAIL APPARATUS

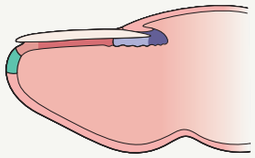

Anatomical region	Keratins (key examples)		Non-keratin proteins
	Soft keratins	Hard keratins	
Nail plate	KRT14, KRT16, KRT17 KRT5, KRT6	KRT31–KRT34 KRT81–KRT84	Ultra-high-sulfur proteins, high-sulfur proteins, high-glycine/tyrosine proteins, trichohyalin
Proximal nail matrix	KRT10, KRT14, KRT15, KRT16, KRT17 KRT1, KRT5, KRT6	KRT31, KRT34 KRT81, KRT85, KRT86	Actin, involucrin, filaggrin*, trichohyalin*, plasminogen activator inhibitor type II, laminin
Distal nail matrix	KRT10, KRT14, KRT20 KRT1, KRT5	KRT31	
Nail bed	KRT14, KRT16, KRT17 KRT5, KRT6, KRT7		Trichohyalin, plasminogen activator inhibitor type II, laminin
Hyponychium	KRT10, KRT14 KRT1, KRT5		Laminin
Tip	KRT16, KRT17 KRT6		
Embryonic nail unit	KRT19		*detected in monkey nails

Fig. 68.11 Distribution of keratins and non-keratin proteins in the nail apparatus. *Adapted from Dawber RP, de Berker DA, Baran R. Science of the nail apparatus. In: Baran R, Dawber RP, de Berker DA, et al (eds). Diseases of the Nails and their Management. Oxford: Blackwell Science, 2001;1–47.*

THE NAIL APPARATUS: BASIC INFORMATION AND TERMINOLOGY	
Nail plate thickness	Toenails are usually thicker than fingernails Toenails: 1.4 mm in women, 1.65 mm in men Fingernails: 0.5 mm in women, 0.6 mm in men
Growth rate	Fingernails usually grow faster than toenails Fingernails: 2–3 mm/month Toenails: 1 mm/month Complete replacement of a nail requires 6 (fingernails) to 18 months (toenails)
Nail plate	Tightly packed cornified cells (onychocytes) arranged in a lamellar pattern; weakly eosin+, strongly acid-fast+; largest on the great toe, covering ~50% of this digit; fingernails have a longer longitudinal axis compared to the transverse axis, while toenails usually have a longer transverse axis
Nail matrix	Epithelium situated above the middle part of the distal phalanx of the digits; keratinizes without a granular layer and generates the nail plate; contains many melanocytes (up to 300/mm^2), predominantly in supra-basal layers
Nail bed	Thin epithelium consisting of 2–5 cell layers with abrupt keratinization and no granular layer; typically no melanocytes
Proximal nail fold	Epithelium with a granular layer; its dorsal part corresponds to the skin of the dorsum of the digit and contains sweat glands but is devoid of pilosebaceous units; densely innervated; the ventral part is thinner and connects with the nail matrix epithelium
Hyponychium	An epithelium equivalent to the volar skin containing granular and thick cornified layers
Nail pigmentation	Banded pigmentation (longitudinal melanonychia) is common in Asian and Black individuals (~75% by age 20 years, nearly 100% by age 50 years); relatively uncommon in White individuals

Table 68.5 The nail apparatus: basic information and terminology. *Courtesy John P. Sundberg, DVM, PhD.*

(see Fig. 68.11). Other molecules and elements within the nail plate include water (normally ~10%–15%, compared to ~15%–25% for the epidermis), lipids (primarily cholesterol), and minerals (e.g. iron, zinc, calcium). The nail plate is relatively porous and ~1000-fold more permeable to water than is the epidermis; as a result, nails can be rapidly dehydrated and hydrated. Low water content in nails leads to brittleness, while nails composed of >30% water are soft and opaque. Although calcium is present in the nail plate, it does not influence the hardness of the nail. Likewise, the white "flecks" that are commonly seen in the nail plate (especially in children) have nothing to do with calcium but rather reflect small disturbances in the compaction of onychocytes, usually related to trauma.

The nail can also contain markers of various metabolic processes and exposures to exogenous substances (e.g. drugs, environmental pollutants). Biomarkers in the nail plate include glycosylated keratin in patients with diabetes mellitus[189], high sodium levels in those with cystic fibrosis[190], and increased amounts of lipids in hyperlipidemic individuals[191]. Exogenous substances that are found in the nail plate in settings of systemic exposure due to environmental contamination include arsenic, lead, and other heavy metals[192,193]. Drugs taken for medical purposes or recreationally may also be present in the nail plate, depending on their binding properties and lipid solubility. Analysis of nicotine in the toenails can be used to track exposure to cigarette smoke via inhalation[194], and a range of narcotics can be identified in nail clippings, either within deposits beneath the free edge of the nail plate due to recent direct contact or incorporated into the nail plate via systemic exposure over previous months[195]. For neonates, it is possible to measure *in utero* exposure to some drugs using nail analysis[196].

Nail Growth

Nail growth is typically measured in the longitudinal axis (e.g. using a vernier caliper) from a defined reference point to the free edge or by monitoring the movement over time of a transverse groove made at the peak of the lunula (Table 68.5)[197]; the mass of nail produced in clippings over a fixed period can also be determined. When a systemic event or local trauma disrupts nail growth for a brief period, a transverse groove reflecting the contour of the proximal margin of the matrix appears and grows outward with the affected nail, allowing the timing of the inciting phenomenon to be estimated. This clinical sign is known as Beau's lines, named after the Parisian cardiologist Justin Beau, who described these bands in patients recovering from typhoid[198].

Multiple physiologic conditions, medical disorders and drug exposures can influence nail growth (Table 68.6). The appearance of decreased nail growth is occasionally explained by substantial thickening of the nail plate that deviates the axis of growth such that nail is accumulating upwards in the vertical axis as well as outward in the longitudinal axis. Examples include onychogryphosis and yellow nail syndrome[199] (see Ch. 71), which are both accompanied by retraction of the proximal nail fold that may normally have a role in molding and flattening the early nail. In these instances, measurement of nail bulk rather than length illustrates that the nails are actually growing, but in a different direction.

Downloaded for Anonymous User (n/a) at Egyptian Knowledge Bank from ClinicalKey.com by Elsevier on March 10, 2024. For personal use only. No other uses without permission. Copyright ©2024. Elsevier Inc. All rights reserved.

Table 68.6 Factors that can influence nail growth.

FACTORS THAT CAN INFLUENCE NAIL GROWTH		
Factor/condition	**Reduction of growth**	**Acceleration of growth**
Age	Elderly	Young
Time of day	Night	Day
Seasons	Winter	Summer
Anatomic location	Toes Thumb, little finger	Fingers Middle finger
Physiologic states		Pregnancy
Extracutaneous disorders	Fever Poor nutrition Denervation, immobilization Infections (e.g. mumps, tuberculosis)	Hyperthyroidism Arteriovenous shunting
Cutaneous disorders	Onychomycosis	Psoriasis, pityriasis rubra pilaris
Drugs	L-DOPA Methotrexate Azathioprine Acitretin	Itraconazole Acitretin (in psoriasis patients)